


PRESENTING CLINICAL SIGNS

History: Grade 3-4/6 left-sided murmur. Coughs after drinking water.

DATE

7/22/22

ECHOCARDIOGRAPHIC FINDINGS

2D, M-mode, and Doppler study.

PERFORMED BY:

Tom McNeill

INTERPRETED BY

 Keith Blass, DVM,
 MS, DACVIM
 (Cardiology)

There is mild left atrial dilation. The mitral valve leaflets are thickened and exhibit systolic prolapse. A moderate jet of eccentric mitral regurgitation is present. There is mild left ventricular dilation. Left ventricular systolic function is mildly hyperdynamic. The aorta and aortic valve are normal. Right atrial and right ventricular dimensions are normal. The tricuspid valve is normal. The pulmonary artery and pulmonic valve are normal. No shunting lesions are visualized. No pericardial effusion or cardiac masses are seen.

PATIENT

Cocoa Smith

 LA - 32.5 mm
 LVIDd - 33.3 mm
 LVIDs - 18.4 mm
 FS - 44.7%
 RA - 18.6 mm
 LVOT - 1.16 m/s
 RVOT - 1.17 m/s

ASSESSMENT/RECOMMENDATIONS

Degenerative mitral valve disease

SPECIES

Canine

BREED

Cockapoo

This examination demonstrates moderate regurgitation of blood across Cocoa's mitral valve resulting from degenerative valve disease. Secondary to her regurgitation, Cocoa has mild dilation of both her left atrium and left ventricle, though her left ventricular systolic function is well-preserved. As only mild left heart chamber dilation is present, Cocoa's current risk for the development of clinical signs secondary to her disease, such as exercise intolerance, syncope, and labored breathing, appears to be relatively low, though careful monitoring for these signs is recommended.

It's unlikely that Cocoa's coughing after drinking water is cardiogenic in origin.

SEX

FS

I recommend starting Cocoa on pimobendan (2.5 mg BID), as this medication should help to slow the progression of her mitral valve disease.

AGE

12 y

A recheck echocardiogram is recommended in 9 months. Thoracic radiographs are recommended if Cocoa experiences difficulty breathing.

WEIGHT

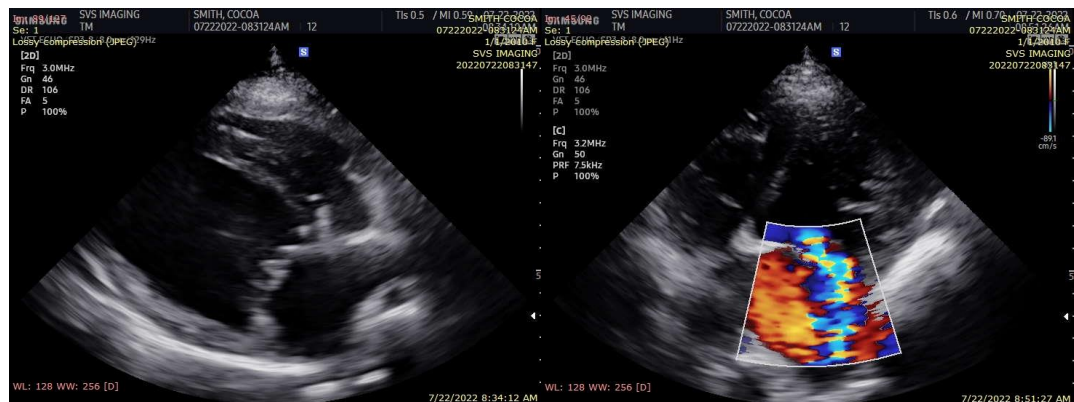
20.2 lb

HOSPITAL NAME

SVS Imaging CT

REFERRING VET

Dr. Seneczko





DATE

7/22/22

The information and recommendations provided are based on the images presented by the referring veterinarian. No evaluation can be communicated regarding pathology that was not visible in the image/video clips provided.

Thank you for this referral. If the clinical or image interpretation does not parallel your findings or if I can be of any further assistance please contact me.

PERFORMED BY:

Tom McNeill

Keith Blass, DVM, MS, DACVIM (Cardiology)
KeithBlass@gmail.com
631-804-5754

INTERPRETED BY

Keith Blass, DVM,
MS, DACVIM
(Cardiology)

PATIENT

Cocoa Smith

SPECIES

Canine

BREED

Cockapoo

SEX

FS

AGE

12 y

WEIGHT

20.2 lb

HOSPITAL NAME

SVS Imaging CT

REFERRING VET

Dr. Seneczko